

# ROUNDTABLE DISCUSSION:

# VERRUCAE



**Do you treat many warts in your practice? If so, approximately how many new patients with warts consult you each month?**

**Ivan Bristow (IB):** It varies but I see about five new patients a month (on one day per week in clinic).

**Anthony Davies (AD):** Warts come in clutches – I probably see between eight and 12 new cases every month on average.

**David Calway (DC):** I frequently treat warts, and probably get six to 10 new patients a month

**Graham Howell (GH):** Yes indeed. I have owned a clinic for nearly 40 years which has three to four podiatrists. I respect the opinions of my colleagues and indeed our patients who wish to see verrucae treated. This is down to patient choice. We treat on average about 10-15 new verruca cases per month.

**Jean Mooney (JM):** I do not treat a great many warts. They seem to have a seasonal presentation (more in spring and summer, less in autumn and winter), I don't have an exact per month that come to my surgery. However, if present it is more likely they will affect children rather than adults. An adult presenting with a verruca is quite likely to have had the lesion for 'years', and their lesions seem to be more difficult to clear than those affecting children. Verrucae tend to affect children or adults who are regular users of community exercise facilities.

**Do you feel as a profession we have moved away from treating warts?**

**DC:** Yes, we have moved away from treating warts partly because of the risk of litigation but because also, as podiatrists, we are used to our patients feeling better after treatment. Following wart treatment however they frequently feel worse! We pride ourselves on relieving pain not causing it

**AD:** I believe that there is a shift away from treating them, yes – not least because the NHS no longer treats them. As a consequence, treatments are not taught I am told, so more patients are turning to private practitioners or self-treating.

**JM:** Anecdotally, my answer is 'yes'. Treatments need to focus on causing breakdown of infected cells to allow the natural immune system to recognise and mount an immune response to the exposed viral material. This is not easily achieved, as the causative virus effectively 'hides' inside the epidermal cells, and thereby avoids the immune system. This message is reaching the profession, and I think is the underlying reason for some colleagues to adopt

a 'wait and see' approach to verruca treatments.

**IB:** This has certainly been the case as up until recently there have been no new treatments available – nothing had changed in 30 years or more (including the outcomes) so I think some podiatrists (and other healthcare professionals) had moved away from actively treating cutaneous warts. Disappointing results from often prolonged treatments (and repeat visits) for patients have perhaps made some practitioners less inclined to treat them.

**GH:** Well the NHS totally moved away it seems. In private practice, when speaking to colleagues, there appears to be a move away from clinic-based treatments in favour of home treatments or none at all. Certainly, there is a diffuse number of opinions as to when, why, if or how to treat verrucae.

**What is your preferred treatment of choice?**

**IB:** Every patient should be judged individually as no one treatment is suitable for all. It is important to explain to the patient the nature of warts and all treatment options and their outcomes before they make any choice. For many patients the 'watch and wait' approach is justified, or simple home treatments first – particularly for children as their warts can resolve quickly. Basic treatments like salicylic acid and formalin-based over-the-counter products are straight forward and generally safe to use at home.

**DC:** A Co<sub>2</sub> 'Cryoprobe' for adults. Salicylic acid, sometimes with monochloroacetic acid, for children. Additionally, I frequently recommend a supplement of Zinc and Vitamin C, taken orally, to boost the immune response.

**GH:** Almost across the board we currently tend to use liquid nitrogen cryosurgery or home treatment advice. We have used almost all treatments during my career. You name it, we've used it. From dandelion juice, banana skins, and marigolds through to surgical excision.

**AD:** No single treatment works for all warts. I tend to change track if the chosen treatment yields no response or a poor response. In no order of preference, I use:

- Liquid nitrogen cryosurgery (a Cry-Ac flask which has varying aperture spray nozzles and long needle narrow attachments. Decant the liquid nitrogen from a 20 litre Dewar)
- Salicylic acid (60%) with or without monochloroacetic acid crystals



**FACILITATED BY  
MIKE POTTER**

Mike was the former Head of Podiatry and Deputy Head of the School of Health Professions and Rehabilitation Sciences and later Director of Learning and Teaching in the Faculty of Health Sciences, University of Southampton. Mike has an ongoing research interest in the treatment and management of verrucae, including the complications that arise from treatments.



**IVAN BRISTOW**

Ivan Bristow is a podiatrist in Southampton, with a specialist interest in dermatology.



**ANTHONY DAVIES**

Anthony qualified as a podiatrist in 1992. He is a private practitioner and independent prescriber.



**DAVID CALWAY**

David qualified at Cardiff in 1975. He was a private practitioner in Yeovil where he remained until retirement earlier this year.



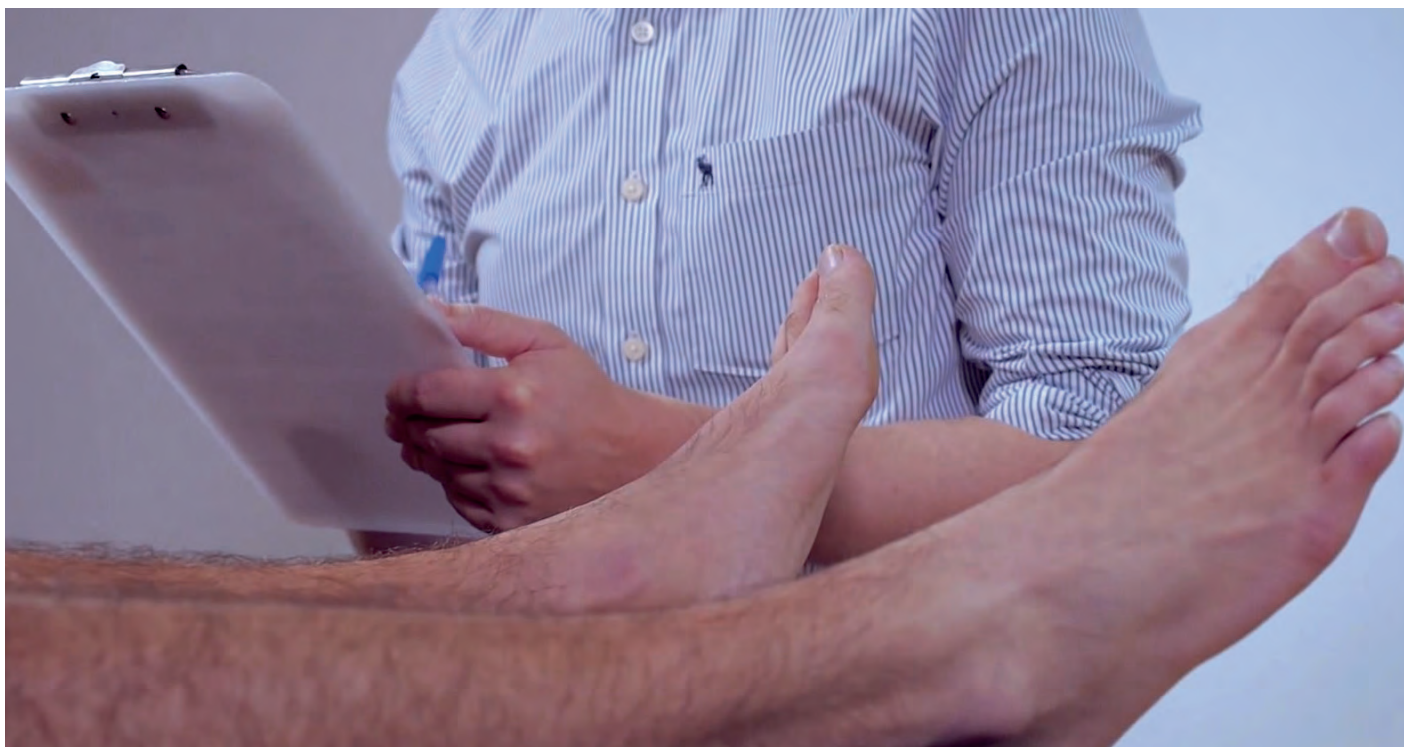**GRAHAM HOWELL**

Graham has been a podiatrist since 1980, working in the NHS in the Dudley Group of Hospitals and Braintree Community Hospital as a consultant podiatric surgeon. He has had a private practice in Saffron Walden for 38 years.



**JEAN MOONEY**

Jean celebrates 40 years in podiatry this year. During this time she has worked in all aspects of health service and private clinical practice, and has had the honour to be appointed podiatrist to the Royal Hospital, Chelsea (the Chelsea Pensioners) for the last 12 years.



- Monochloroacetic acid plus silver nitrate (75%)
- Needling
- Swift microwave
- Imiquimod (Aldara), which I prescribe off-label
- Topical glutaraldehyde as a home treatment
- Occasionally I am asked for Thuja tincture
- No intervention is advised if the patient is asymptomatic
- Home treatment in younger children as they often do not cope well with more aggressive treatments which can be painful.

Caustics are becoming less popular as a first-line treatment due to the challenge of keeping the foot dry for three days compared to years ago when we all only bathed once a week! I tend to encourage the patient to decide which treatment appeals to them most after giving them the risks/benefits of all the treatments available – unless I feel a particular treatment is indicated and likely to give a good result.

**JM:** I usually adopt either one of two approaches:

- Encourage the patient to self-treat the lesion (once it has been diagnosed), with a topical agent, such as 'Occlusal', purchased over the counter from the pharmacy, together with written advice (follow the manufacturer's advice leaflet, keep the lesion covered, do not pick at the lesion, etc.), and to try this approach for at least six months, as

many lesions (approximately a third) may self-resolve within that time.

- Apply a caustic for one week then use cryosurgery on the lesion. This approach is successful in around a third of presenting cases.
- It is essential to explain to the patient that the warts will only clear when the immune system kills off or overcomes the viability of the virus: whatever I do may (or may not) accelerate that process.

It should be remembered that the vascular status of the foot of any patient who undergoes chemical cautery or other treatment for a verruca that induces a degree of tissue damage must be assessed. It is essential that the foot has a good blood supply, so that the healing phase of the treatment occurs. Thus, patients with peripheral arterial disease or other forms of vascular compromise such as Raynaud's disease, those with diabetes mellitus, those on systemic steroid therapy or taking other immunosuppressant medications may not be suitable to undergo tissue-destructive lesion therapies.

#### What treatments, in your experience, are most likely to produce complications?

**DC:** Cryosurgery often results in haematoma formation, but in my view monochloroacetic acid produces the more worrying complications.

**GH:** This is an easy one; salicylic acid with a juicy crystal of monochloroacetic acid pushed through to the verruca. I

have had more emergency calls and painful breakdowns or reactions than in all the surgical cases I've ever done. We do not even consider it as a treatment now. Though, on talking with colleagues, it is still widely used. A runner-up to this is surgical excision and its re-infections of the wound and then cryosurgery with its painful, sometime spectacular, haematomas.

**AD:** Caustics and cryosurgery. Care must be taken not to 'over-egg the pudding' when using caustics, and likewise cryosurgery should be used with caution on areas of thinner skin. Interestingly, plantar heel warts are often more prone to complications, such as over-breakdown and/or infection. It is so important to make the patient aware of possible complications and to flag them up if they are the least bit concerned that something is going wrong.

**JM:** Over-aggressive treatments; especially in cases where the patient has self-diagnosed the nature of the lesion, and 'tried everything' (such as topical caustic ointments, proprietary cryosurgery treatments and so on) that they can purchase from the pharmacy. Applying these one after another, without allowing sufficient time between treatment applications, can produce complications. I have treated patients who have taken this approach and thereby induced severe tissue breakdown and subsequent forefoot infection, due to their misguided expectation, and disappointment at the lack of an instant and immediate lesion 'cure'.

**Note:** There should be a period of discussion between practitioner and patient once the diagnosis of a verruca has been made. The patient should be able to ask questions to help them understand the nature of the problem and the pros and cons of the various treatment options. The patient must also be allowed to opt for 'no treatment' if that is their preference, but they will need to understand the possible consequence of spread of infection. Some cases may undergo spontaneous resolution, but equally the infection may increase and cause more lesions, as well as possibly infecting other family members. The patient should understand that no treatment can guarantee successful resolution. You should reinforce the message that there is no 'quick fix', and it is likely that they will need to undergo a course of treatments to try to achieve resolution, which can prove expensive if the patient is being treated privately.

**IB:** All treatments have the potential for complications. In my own experience, acids and liquid nitrogen have produced the most complications, and patient responses can be unpredictable. Research has shown that, to be effective with liquid nitrogen, the operator must be aggressive in their approach, but this in turn increases the risk of problems. Individual patient responses to cold can be very varied. I have seen most problems arise in instances where acids have been mixed.

#### What are the typical complications you see following treatment and how do you manage them?

**IB:** The key to managing complications is communication with the patient. Before embarking on any treatment, I always take time to explain any complications to the patient. If the patient is aware and they do arise, it is less of a shock and less likely to end in problems.

**AD:** With liquid nitrogen cryosurgery, if you over-freeze, you can get a 'blueberry' type of blister, which can be alarming to the patient; or caustics can cause too much tissue destruction, and track to deeper structures, and cause infection. Acid antidote advice is always given to pre-empt complications, such as bicarbonate of soda, and warm saline footbaths, with the caveat that the patient must return as soon as possible if they feel things are not going to plan. If infection develops, which is rare, I prescribe antibiotics (specifically clarithromycin bd for children). Complications are fortunately infrequent, but do occur occasionally, however careful you are.

**DC:** I estimate that cryosurgery results in haematoma about 20% of the time but I would only regard haematoma a complication if large and particularly painful. I prefer to keep haematomas intact but if excessively painful and large I ask patients to return and I drain and dress them.

Following chemical cautery, patients often experience some pain, inflammation, swelling and sometimes tissue breakdown. If the pain is excessive or worrying, I advise patients to remove the dressing and soak the foot in cold saline and return as soon as possible for release of fluid and protective dressing if required.

There is a very fine line between effective treatment and an excessive reaction. For instance, a haematoma after cryosurgery undoubtedly results in more discomfort but by the same token bodes well for the resolution of the lesion. If patients are adequately forewarned, any reaction is more likely to be regarded as efficient rather than excessive.

**JM:** Thank goodness, complications are rare, but all treatments and their likely outcomes (including that of no successful resolution of the lesion and possible scarring) should first be explained to and discussed with the patient.

**GH:** Our main armoury of treatments now consists of Cuplex gel, used merely as a conservative home treatment to prevent spread, Thuja occidentalis as a systemic course of homeopathic tablets, or liquid nitrogen cryosurgery (-196°C) closed-end probe freezing as thermal destruction. Surgical treatment includes dry needling, or radiosurgery for larger quantities of small sized lesions, and laser or excision surgically for a few single growths.

We use an algorithm of escalating invasiveness of treatment dependent on health and age of the patient, severity of infection, size (small, large or mosaic), site of the lesion, weight bearing versus non-weight bearing, and anhidrotic versus hyperhidrotic foot types.

So, if we have a small child sitting in front of us with eyes wide in fear, then we are likely to suggest using Cuplex weekly, i.e. to stop spread and await the immune system response without spreading the verrucae over other areas of the feet or to other people.

In another example a patient that attends covered in mosaics verrucae will likely get a 14-day course of 6x 30x 200x potency Thuja occidentalis, and if unsuccessful moving to a Photobiomodulation Therapy (PBMT) laser course.


In the case of one or a few satellite growths we are likely to lean towards cryosurgery. But it's all down to patient choice, which takes into consideration pain, risk, cost, convenience and likely outcomes.

#### If you use cryosurgery (liquid nitrogen, nitrous oxide, Cryospray, etc) what treatment regime do you use? Do you use freeze/thaw cycles?

**IB:** I tend not to use these now.

**AD:** Generally (with liquid nitrogen) 2 x 15 seconds or 3 x 10 second freeze-thaw cycles, and review at not less than three weeks, as the basal layer may not have recovered sufficiently to re-freeze.

**DC:** Usually (with carbon dioxide cryoprobe), a 20-30 second freeze. If the lesion thaws very quickly, I will give a further 15-second freeze.

**GH:** I started with nitrous oxide in the 80s and converted to liquid nitrogen when the first Dewar-type spray flasks were introduced. Liquid nitrogen is colder than nitrous oxide so in theory is less painful as it freezes more quickly. But it's still not pleasant. We did adopt freeze thaw along with all its theories, but have wandered into single, longer freeze cycles as it was often hard to expect patients to accept a re-freeze of the highly sensitised area twice in the same session. The results seem to be the same. The average freeze time is about one minute with a closed-end probe. We attempt to achieve a maximum depth of freeze without expanding the ice too much wider than the lesion. To achieve this, we choose a probe slightly smaller than the lesion itself and monitor the ice ball size. 

“

*IT IS SO IMPORTANT TO MAKE THE PATIENT AWARE OF POSSIBLE COMPLICATIONS AND TO FLAG THEM UP IF THEY ARE THE LEAST BIT CONCERNED THAT SOMETHING IS GOING WRONG.*

**ANTHONY DAVIES**

**JM:** I do not have access to liquid nitrogen in my surgery, as I cannot justify the cost of appropriate storage in relation to the number of verrucae I see, and thus I use Cryospray as a means of cryosurgery. To increase the effectiveness of this technique, I apply a caustic ointment to the lesion for one week. At the return appointment, all macerated parakeratosis overlying the lesion can be cleared away with a scalpel, thereby reducing the insulating effect of the overlying thickened epidermis, so that when the freezing mixture is applied the lesion temperature can be reduced to a level at which the infected epidermal cells within the basal cell layer will rupture (the nucleus of virus-infected cells needs to be reduced to  $-24^{\circ}\text{C}$ , or colder to rupture the cell and expose its contents and incite an immune response to the virus).

**Note:** All proposed lesion treatments should be supported by the patient's signed consent.

My preferred method is as follows:

- Debride all overlying callosity/parakeratosis from the verruca (warn patient that this will induce it to bleed).
- Mask the lesion (make a 2cm diameter, circular piece of strapping with three layers of Mefix or zinc

oxide strapping, one on top of the other. Cut a hole in the middle of this, which is just smaller than the diameter of the lesion, and apply to the skin, so that the hole lies directly over the lesion and not the unaffected skin.

- Cut and bevel a pad (e.g. a plantar cover) from semi-compressed felt, and make a small cavity in the 'sticky' side of the pad that corresponds exactly to the lesion site. Fill the cavity with 70% salicylic acid ointment, and place a tiny amount of monochloroacetic acid crystals on the surface of the salicylic acid ointment (approximately three or four crystals; each crystal being the size of a grain of table salt, NOT sea salt). Affix the pad to the foot so that the monochloroacetic acid and salicylic acid lie directly over and in contact with the lesion. Strap the pad securely in place.
- Instruct the patient to keep the foot dry and the pad *in situ* until their next appointment in seven days' time. Also advise the patient that it is normal to experience some discomfort, due to the effect of the applied acid, but to make contact before the next appointment if the

pain becomes unbearable.

- At the next appointment, debride the lesion of all macerated overlying skin (the lesion will probably bleed). Apply the cryosurgery as per the manufacturer's instructions (I usually cover the lesion with a small amount of water gel to focus the freezing action at the lesion site. Freeze the lesion for three cycles (one minute freeze + one minute thaw) then re-pad (without any caustic). Warn the patient of likely discomfort (you are, in effect, creating an area of frostbite to try to destroy the lesion, as well as causing cellular rupture to trigger an anti-viral immune response).
- Ideally, the freezing cycles should be repeated once every three weeks until the lesion resolves.

If using a liquid caustic (e.g. monochloroacetic acid solution) a mask is NOT indicated, as the liquid would soak into the mask material, and extend the area of caustic action beyond the borders of the skin lesion.

**Do you use 'chemical cautery' treatments such as monochloroacetic acid, pyrogallol acid, or anything similar? If so, what treatment regime do you use? If these unlicensed medicinal products were to be withdrawn from use what would be your feeling?**

**GH:** Been there, done it, read the book. Yes, we've used it all. Monochloroacetic acid on its own is very painful, hence mixing it with salicylic acid 40% makes it somewhat more acceptable. The lesion must be masked to protect the surrounding skin. I used to use Benzoin Tincture to protect the skin around the lesion, mask with tape, then apply an aperture cover of felt. I filled this with salicylic acid then pushed a crystal of monochloroacetic acid through the salicylic acid ointment onto the lesion. I reviewed after a week and continued until a breakdown occurred and the lesion cleared. The patient had to keep their foot taped up and dry for quite a few weeks in succession. It was a bit like Russian roulette when the breakdown would occur, but it could be quite violent on occasion. We just do not use it anymore, as it has given way to more modern and controlled treatments, although these require investment.

With regards to the possible removal of unlicensed medicines, this would be disastrous and must be resisted. In particular, we must not lose phenol. Pyrogallol acid, gentian violet and

